QUESTION 3

My patients complain about food impaction around single implant restorations. Can this be managed and how can I prevent it?

Background

There are many reasons for food impaction, but it may occur more often around implants because they are different from natural teeth in many respects. When a natural tooth is extracted, there is often a loss of interproximal papilla, which may not be recreated with an implant restoration. A larger issue is the fact that healthy implants exhibit no mobility, whereas natural teeth move varying degrees based on their periodontal condition and the forces placed on them. This movement is not very noticeable until an implant becomes a point of reference and movement of natural teeth becomes obvious (in relation to the stationary implant). The difference in movement makes both placement of a restoration with an adequate interproximal contact and maintenance of the contact difficult. During the recall period, when we examine occlusion as well as interproximal contacts, neighbouring teeth have often moved causing an opening of the contact (**Figs. 1, 2a** and **2b**).

An open contact is associated with impaction of food debris in soft tissue and caries in the neighbouring teeth caused by inadequate cleaning of the interproximal debris. As the contact opens further, restoration of neighbouring teeth may be required due to caries (**Fig. 3**). If left unchecked, caries can lead to a need for endodontic treatment and even extraction.

Prevention and Treatment

The possibility of implant contacts opening must be considered during treatment planning. The patient must be told that although the success rate of implants is excellent, the crowns that are placed on the implants will need maintenance. Additional efforts are also needed because of the differential movement of implants versus natural teeth. Initial contacts are made broad and flat with solid resistance to removal of floss. Prevention of damage to neighbouring teeth is essential and, at recall visits, not only must the implant be examined, but the adjacent teeth must also be evaluated for possible carious involvement.

Once a contact opens, treatment is designed to close it. If the restoration is cemented in place over an implant abutment and cannot easily be removed, bonding resin on the approximating surface of the neighbouring tooth should be considered if that surface is suitable for bonding (enamel or dentin). If caries has developed, it must be treated. If the neighbouring tooth has been previously restored with a full coverage cast restoration, the restoration may have to be replaced (**Fig. 4**). The contact is then made tight, but the patient must be made aware that there is still potential for movement and treatment may be needed again.

If the patient does not want the neighbouring tooth adjusted, the contact can be closed by slot preparation of the implant crown surface, etching with hydrofluoric acid, silanating the ceramic surface, then bonding composite resin to the area (**Fig. 5**).

This treatment is easier if the crown placed on the implant is designed to be removed when necessary. This can be accomplished by creating a

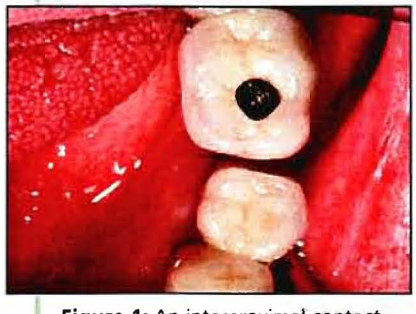

Figure 1: An interproximal contact has opened between the second premolar and first molar due to mesial movement of the second premolar.

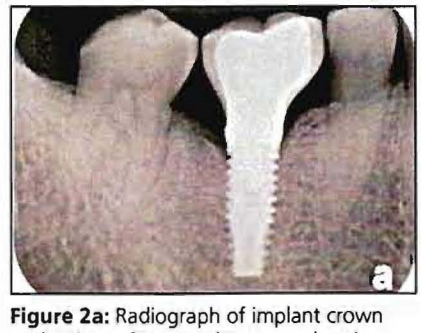

Figure 2a: Radiograph of implant crown at the time of crown placement showing acceptable mesial contact.

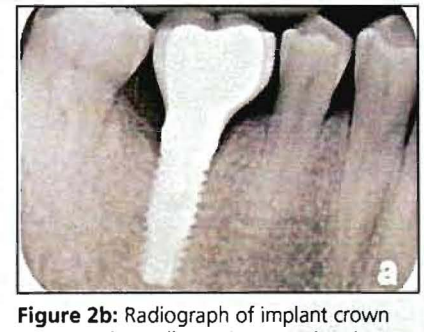

Figure 2b: Radiograph of implant crown at 6-month recall appointment showing an opening mesial contact.



Figure 3: An open mesial contact between an implant (45) and tooth 44 has allowed caries to develop on the distal surface of tooth 44

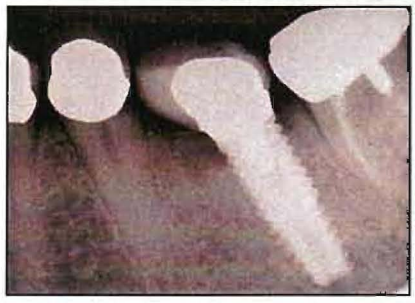

Figure 4: An open mesial contact on the implant in the 36 position has allowed collection of debris and development of caries at the gingival crown margin of tooth 35. The crown on tooth 35 was replaced.

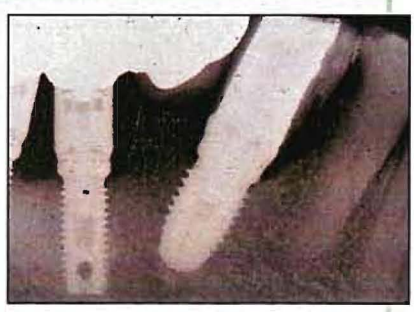

Figure 5: An open contact has been restored by cutting into the restorative material along the mesial edge and bonding additional material to it. The carious lesion in the distal surface of tooth 44 must now be restored.

Figure 6: Attempts to add new porcelain to a prosthesis that has been in the mouth for an extended period often causes catastrophic failure of existing porcelain. Fractured porcelain must be stripped from the metal substructure and replaced.

Figure 7: Rather than porcelain, laboratory-cured composite resin can be applied to metal and serve as a final restoration. In future, new material can be easily added intraorally.

screw-retained crown or a cemented crown using temporary cement or built-in design mechanisms allowing easy removal. The crown can then be removed from the mouth and the porcelain removed from its substructure and reapplied to a greater interproximal dimension. Note: new porcelain cannot be added to old porcelain that has been in the mouth for an extended period; therefore, porcelain must be replaced. Forward planning is useful, as one can design the final restoration from material that is easily bonded to so that future additions and repairs are better supported (**Figs. 6** and **7**).

Implant dentistry is an excellent way to replace missing teeth. However, because natural teeth and implants move differently, one must be vigilant during the maintenance phase of implant dentistry.

THE AUTHOR

Dr. Izchak Barzilay is head of the division of prosthodontics and restorative dentistry, Mount Sinai Hospital, and assistant professor, faculty of dentistry, University of Toronto, Toronto, Ont. He also maintains a private practice (Prosthodontic Associates) limited to prosthodontics and implant dentistry in Toronto. Email: ibarzilay@buildyoursmile.com.

QUESTION 4

If I extract a tooth, can I use its crown as a pontic for a fixed prosthesis?

Background

Bonding an extracted crown in place was recommended to create an early form of resin-bonded prosthesis. Initially, composite resin was applied interproximally to temporarily secure the natural tooth pontic in place until healing could occur. The tooth would then be replaced by a more conventional restoration. In cases where an interim prosthesis is not available, use of the extracted crown is effective and expedient. Various factors, including the condition of the coronal portion of the extracted tooth, the condition of the neighbouring teeth (coronal and periodontal) and the ability to adequately isolate the region, are important considerations when deciding if this interim treatment modality is to be used.

For a longer-term restoration, the conventional bonded prosthesis (resin-bonded bridge or Maryland bridge) is an attractive option, in that it requires minimal tooth preparation and can be completed relatively quickly. The success of this type of restoration depends on adequate tooth preparation, adequate mechanical strength of the restoration, control of the forces placed on the final restoration and proper cementation procedures during placement of the restoration. With the development of bonding methods and materials to connect metals, ceramics, composite resins and tooth structure to each other, the resin-bonded application is not only effective but can also be esthetically pleasing, long lasting and functional. Simply bonding the crown of a tooth in place interproximally may serve as a short-term solution, but over time, this form of prosthesis will probably fail because of debonding and fracture.

This article presents a case in which a natural tooth crown was bonded to neighbouring teeth with the intention of its being used as a longer-term restoration.

Clinical Case

A 70-year-old woman presented for dental treatment. After an extended assessment of vertical dimension, her posterior occlusion was restored with conventional porcelain-fused-to-metal restorations. The patient was concerned about re-creating the natural esthetics of her anterior teeth and asked whether a lingually based restoration could be fabricated to preserve the esthetics on the buccal surface of the anterior teeth. Minimal preparation of the lingual surfaces of the anterior teeth was performed, and lingual veneers with incisal coverage were fabricated (Empress, Ivoclar, Schaan, Lichtenstein) and bonded with a dual-cure composite resin cement (Nexus II, Kerr Corporation, Orange, Calif.) (**Fig. 1**).

Three years after placement of the original restorations, the root of the upper right central incisor was fractured while the patient was chewing on a popcorn kernel (**Fig. 2**). The root had to be removed, and replacement of the tooth was indicated. The patient was concerned about matching the shade and texture of a new restoration to the original (unrestored) buccal surface. The decision was made to use the natural crown and the lingual-veneered tooth as a pontic for the long-term restoration.

A lingual groove-and-slot preparation was created through the cingula of the lingual veneers of the maxillary anterior teeth. A deeper preparation

Figure 1: Buccal view of incisal extensions of the lingual veneers, which were placed to maintain new vertical opening.

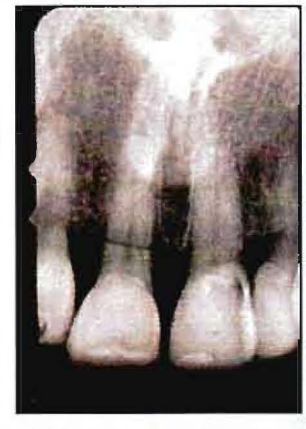

Figure 2: Radiograph of tooth 11 showing a horizontal root fracture.

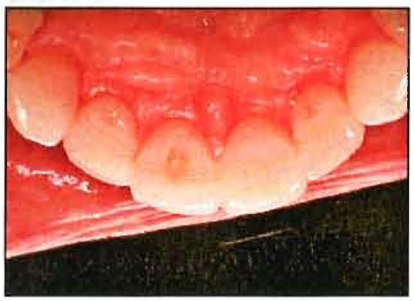

Figure 3: Occlusal view of the lingual veneers, with a slot preparation and deeper preparation of tooth 11.

Figure 4: Metal frame cast so as to be short of all margins.

Figure 5: Metal frame laminated with porcelain to fit all margins; it is ready for cementation.

Figure 6: Tooth 11 after extraction, ready for bonding of the restoration.

Figure 7: The extracted crown connected to the metal frame, ready for bonding to the abutment teeth.

Figure 8: The prosthesis bonded in place; esthetics have been maintained.

into the fractured tooth allowed for more accurate indexing of the future prosthesis (**Fig. 3**). A polyether impression was made, and a nonprecious metal frame was fabricated (Press Alloy, Swiss NF, Toronto, Ont.). This frame was designed to be short of the prepared margins (**Fig. 4**). The frame was opaqued and waxed to create the ideal shape for the retainer (i.e., to fit the prepared channel) and porcelain was applied using the pressing method (SNF Press Ceram, Swiss NF) and finished (**Fig. 5**). This porcelain-fused-to-metal frame was tried in, the fit was assessed, and the ceramic portion was etched with hydrofluoric acid (Pulpdent Corp, Watertown, Mass.).

The region of tooth 11 was anesthetized, and the crown and root were extracted atraumatically; good hemostasis was achieved (**Fig. 6**). The crown portion was swabbed with 100% ethanol, and a composite resin plug was bonded to the underside of the crown to seal the internal chamber of the crown. The lingual surface of the crown (lingual ceramic veneer) was then etched with hydrofluoric acid for 5 minutes. The etched porcelain-fused-to-metal frame was then silanated, as was the crown, and the 2 units were bonded together with a dual-cure composite resin cement (Nexus II) (**Fig. 7**).

The anterior teeth were then isolated using a rubber dam. The prepared lingual surfaces were cleaned with pumice, rinsed and dried. The lingual veneered surfaces were etched with hydrofluoric acid, and both the new restoration and the intraoral veneers were treated with silane and cemented with C&B Metabond (Parkell, Farmingdale, N.Y.). Occlusion was verified, and oral hygiene instructions were given (**Figs. 8–10**).

Discussion

This report has described use of a natural tooth pontic in an esthetically demanding area. Using the natural tooth maintains the overall esthetics and makes it simpler to ensure the ideal contour and shade. However, there is some concern about the longevity of the shade. Hydration of this type of pontic is no different than for an endodontically treated tooth, and as such the colour should not change dramatically (**Fig. 11**). In the case described here, the design of the previous restoration

Figure 9: Occlusal view of the prosthesis in place.

Figure 10: Anterior periapical radiograph showing the restoration in place.

Figure 11: Follow-up photograph of the region 12 months after treatment, showing excellent healing and colour stability.

made it difficult to achieve an esthetically pleasing result, and use of the extracted crown solved many potential esthetic problems. When the tooth was extracted, the crown was shaped to create an ovate pontic and thus maintain gingival esthetics. Since both abutment teeth were periodontally sound, a fixed restoration was considered ideal.

In this case, a metal-based supporting structure strengthened the prosthesis and allowed for a longer-term restoration. The patient was also interested in minimizing the amount of metal that was visible once the restoration was positioned. This was accomplished by laminating the metal with porcelain using a pressing system to develop an accurate contour. A nonprecious metal was used because of its strength in thin section and the capacity for chemical and mechanical bonding to the alloy.

In conclusion, it is possible to use extracted teeth as pontics for either short-term or long-term restorations. Key elements are the addition of a metal supporting component, adequate tooth preparation and bonding of all materials to each other under isolated conditions (rubber dam).

THE AUTHOR

Dr. Izchak Barzilay is head of the division of prosthodontics and restorative dentistry, Mount Sinai Hospital, and assistant professor, faculty of dentistry, University of Toronto, Toronto, Ont. He also maintains a private practice (Prosthodontic Associates) limited to prosthodontics and implant dentistry in Toronto. Email: ibarzilay@buildyoursmile.com.